

PennHIP Report

Referring Veterinarian: Dr Matthew Dikeman
Email: bahxrays@gmail.com

Clinic Name: Brittmoore Animal Hospital
Clinic Address: 1236 Brittmoore Rd.
Houston, TX 77043
Phone: (713) 468-8253
Fax: (713) 468-8995

Patient Information

Client: Druckenbrodt, Lori
Patient Name: Faith
Reg. Name:
PennHIP Num: 178595
Species: Canine
Date of Birth: 01 Sep 2019
Sex: Female
Date of Study: 01 Sep 2022
Date of Report: 04 Sep 2022

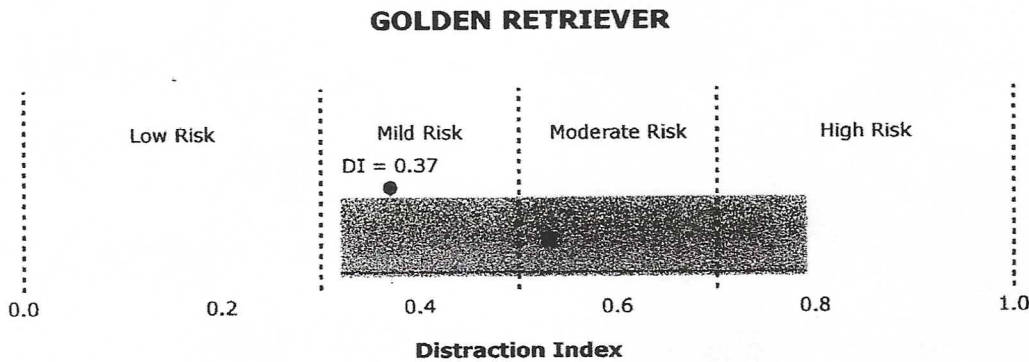
Tattoo Num: n/a
Patient ID: 123656
Registration Num: n/a
Microchip Num: 956000011844792
Breed: GOLDEN RETRIEVER
Age: 36 months
Weight: 60 lbs/27.2 kgs
Date Submitted: 03 Sep 2022

Findings

Distraction Index (DI): Right DI = 0.34, Left DI = 0.37.
Osteoarthritis (OA): **No radiographic evidence of OA for either hip.**
Cavitation/Other Findings: No cavitation present.

Interpretation

Distraction Index (DI): The laxity ranking is based on the hip with the greater laxity (larger DI). In this case the DI used is 0.37.
OA Risk Category: The DI is between 0.31 and 0.49. This patient is at mild risk for hip OA.
Distraction Index Chart:



BREED STATISTICS: This interpretation is based on a cross-section of 24700 canine patients of the GOLDEN RETRIEVER breed in the AIS PennHIP database. The gray strip represents the central 90% range of DIs (0.32 - 0.79) for the breed. The breed average DI is 0.53 (solid square). The patient DI is the solid circle (0.37).

SUMMARY: The degree of laxity (DI = 0.37) falls within the central 90% range of DIs for the breed. This amount of hip laxity places the hip at a mild risk to develop hip OA. **No radiographic evidence of OA for either hip.**